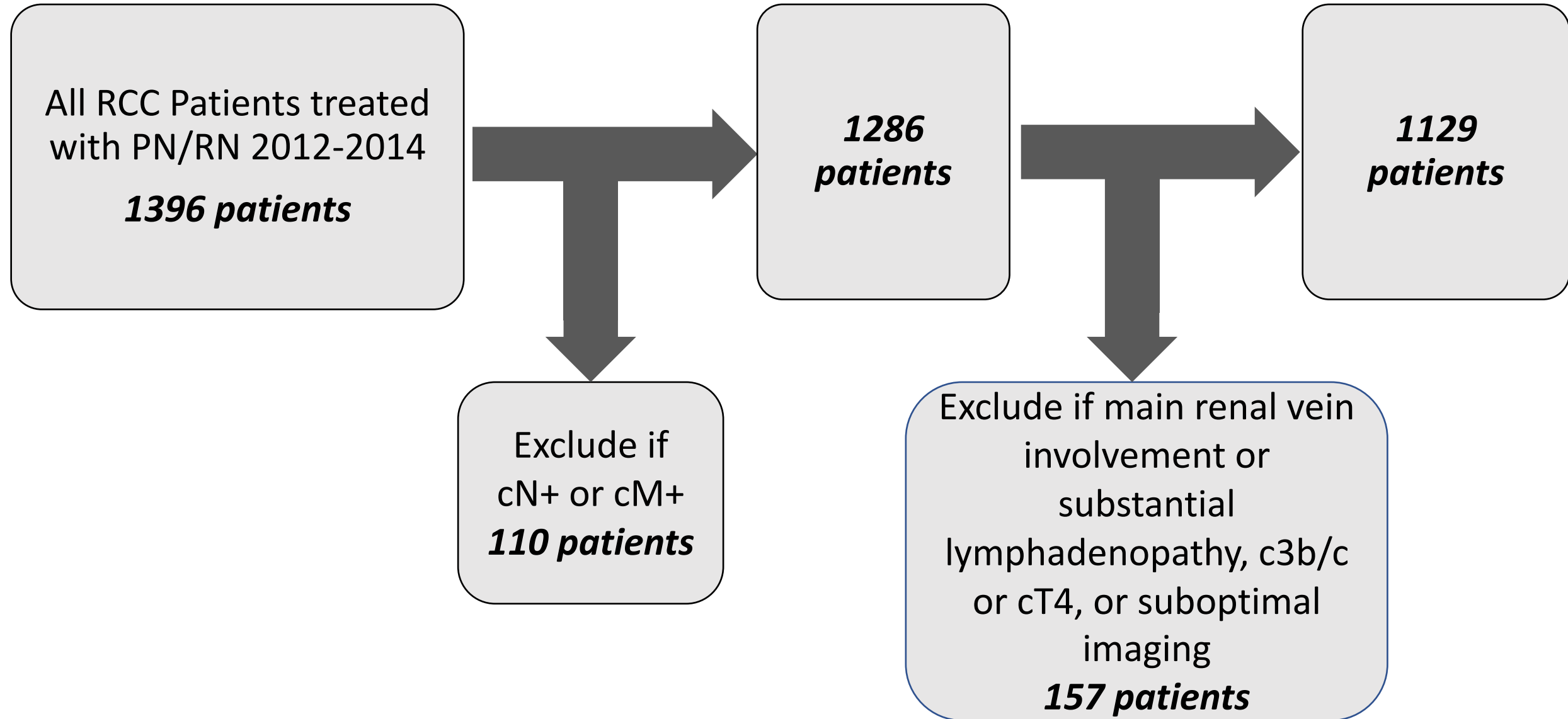
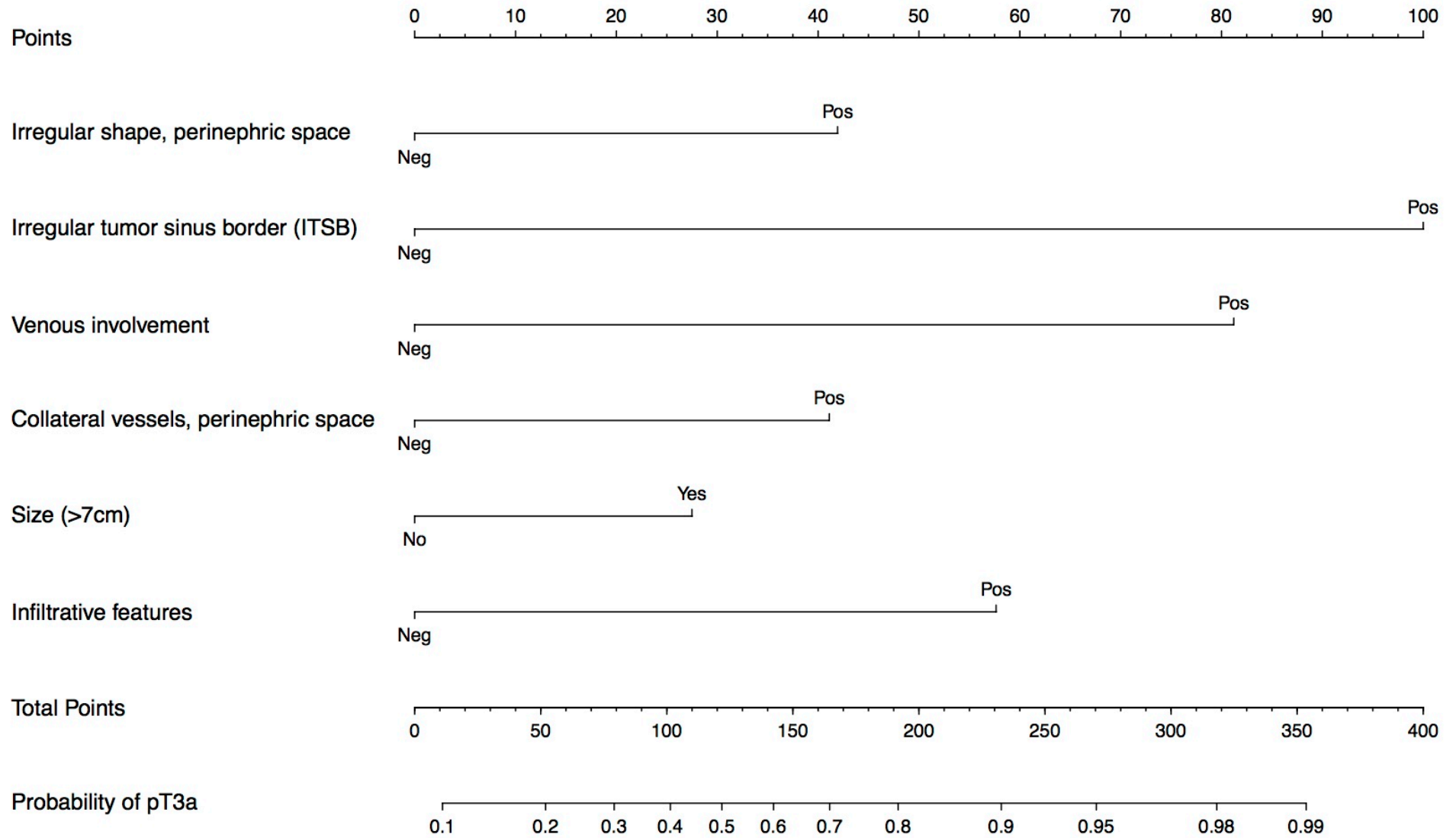


**Supplementary Figure 1. Algorithm for patient selection.** Exclusion criteria included: poor imaging quality, clinical stage other than cT1-T3aN0M0, and main renal vein involvement or substantial lymphadenopathy. Substantial lymphadenopathy was defined as >1.5cm lymph node burden in the ipsilateral retroperitoneum.



**Supplementary Figure 2. Nomogram for prediction of pT3a status based on pre-operative imaging characteristics.** Irregular tumor sinus border (ITSB) proved to be the most powerful predictive factor on all such multivariable analyses. Incorporation of additional factors beyond ITSB and tumor size failed to improve the C-index. The nomogram shown represents the best that could be developed when other features were added to ITSB and tumor size.



C = 0.84